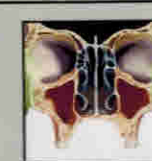
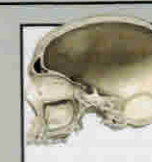










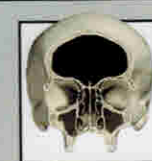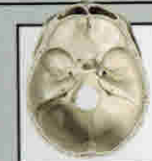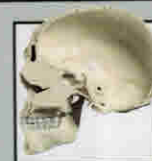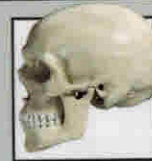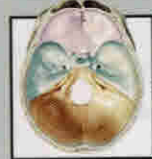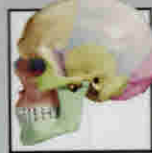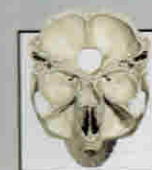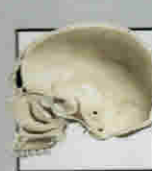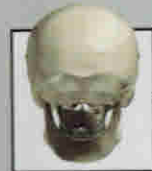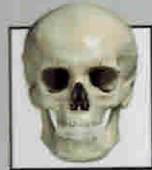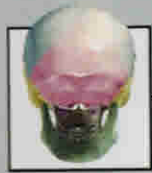
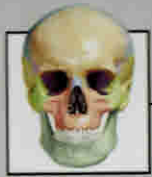

CONTENTS

	01 SKULL	10
	02 CEREBRAL HEMISPHERES	30
	03 BRAINSTEM AND CEREBELLUM	50
	04 CRANIAL NERVES	66
	05 ARTERIES	100
	06 VEINS	120
	07 VENTRICULAR SYSTEM	134
	08 CISTERNS	148
	09 FUNCTIONAL SYSTEMS	160
	10 FIBRE CONNECTIONS	176
	11 VERTEBRAL COLUMN AND SPINAL CORD	200
	12 SURGICAL ANATOMY	212
	Index	234
	References	246

SKULL



12 Cranial Bones

13 Cranial Bones

14 Cranial Bones

15 Cranial Bones

16 Anterior View

17 Lateral View

18 Posterior View

19 Medial View

20 Exterior of the Calvaria

21 Interior of the Calvaria

22 Skull Base

23 Skull Base

24 Lateral Wall of the Nasal Cavity

25 Orbit and Neighboring Structures

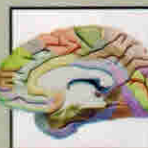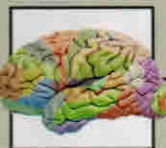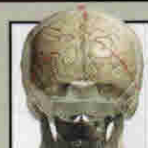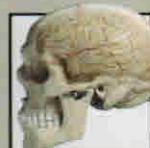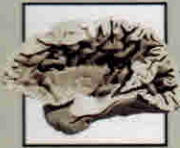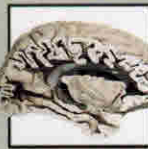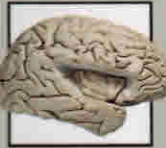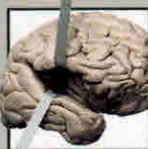
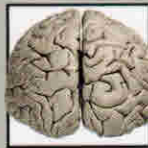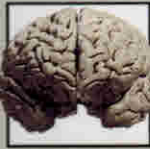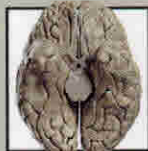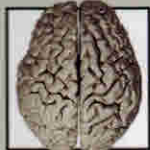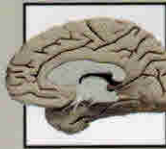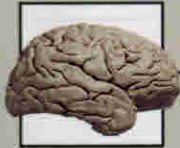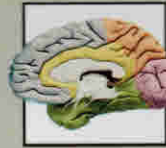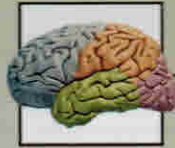26 Axial Slice

27 Sagittal Slice

28 Bones of the Orbit

29 Bones of the Orbit

CEREBRAL HEMISPHERES



32 Cerebral Lobes

33 Cerebral Lobes

34 Lateral View

35 Medial View

36 Superior View

37 Inferior View

38 Anterior View

39 Posterior View

40 Insular Lobe

41 Insular Lobe

42 Insular Lobe

43 Insular Lobe

44 Sagittal Section

45 Axial Section

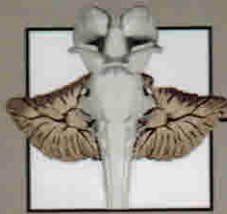
46 Projections of the Sutures

47 Projections of the Sutures

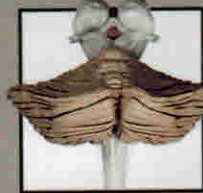48 Brodmann Areas

49 Brodmann Areas

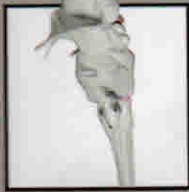BRAINSTEM AND CEREBELLUM



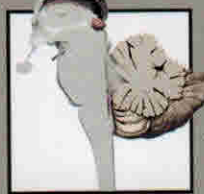52 Anterior View



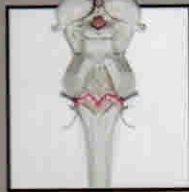53 Posterior View



54 Lateral View



55 Medial View



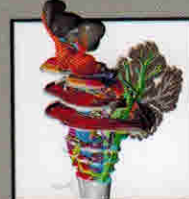56 Posterior View



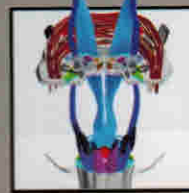
57 Cerebellum



58 Sections of the Brainstem



59 Sections of the Brainstem



60 Sections of the Brainstem. Level of the Decussation of the Pyramidal Tract



61 Sections of the Brainstem. Level of the Trigeminal Nerve



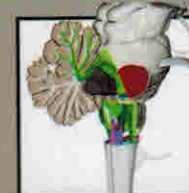
62 Sections of the Brainstem. Level of the Inferior Olive



63 Sections of the Brainstem. Level of the Cerebral Peduncle

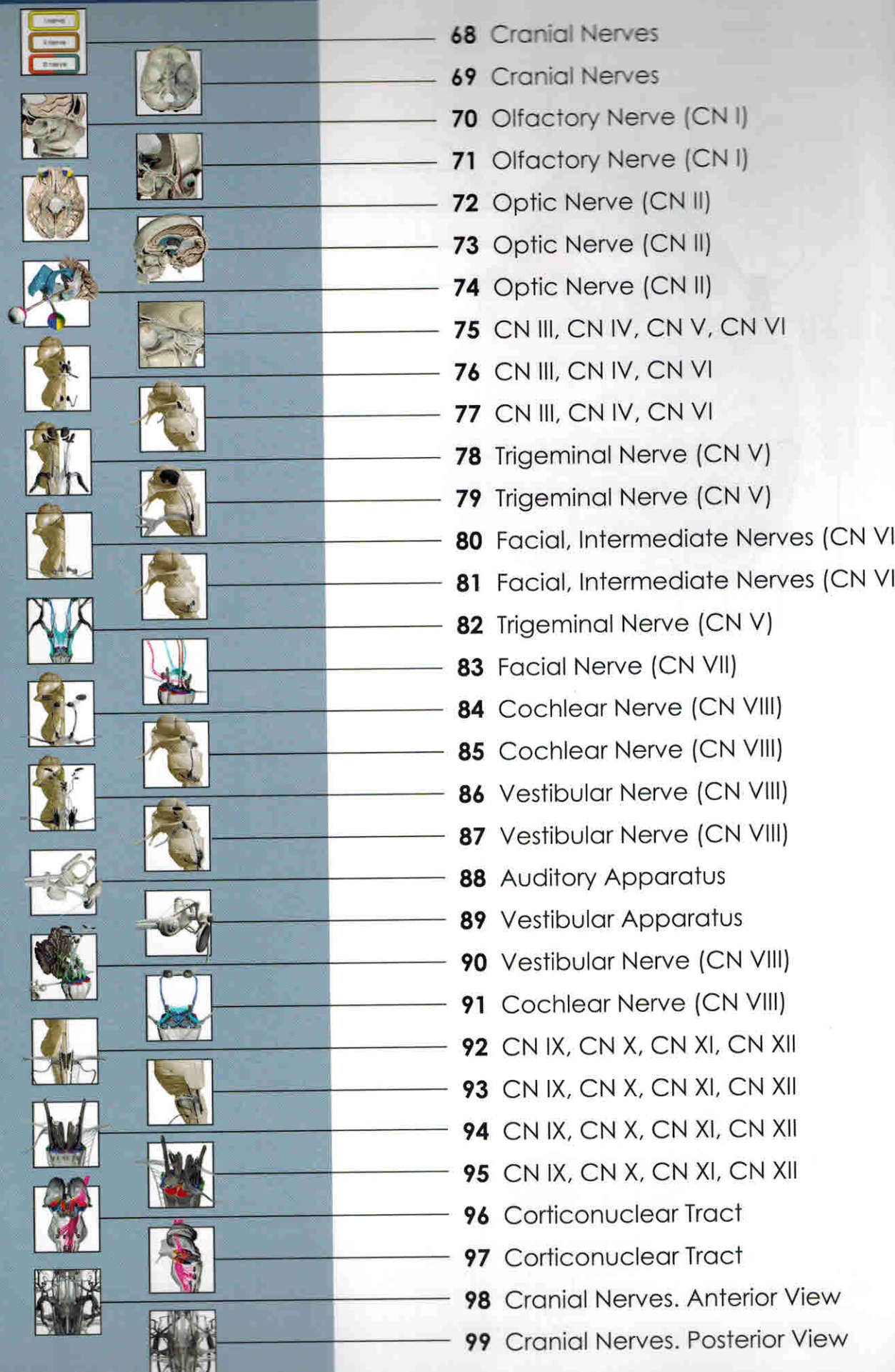


64 Sections of the Brainstem. Level of the Middle Cerebellar Peduncle

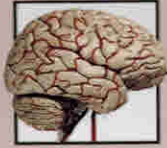

64 Sections of the Brainstem. Level of the Superior Cerebellar Peduncle

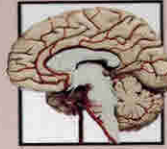CRANIAL NERVES



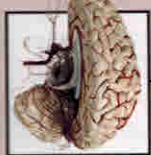ARTERIES



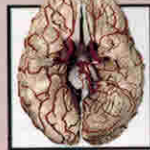102 Lateral View



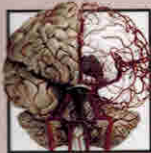103 Medial View



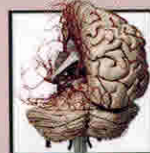
104 Superior View



105 Inferior View



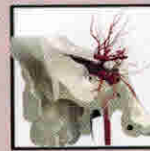106 Anterior View



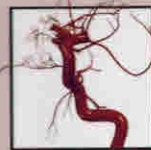107 Posterior View



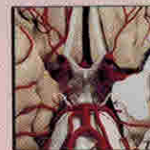108 Internal Carotid Artery



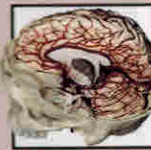
109 Internal Carotid Artery



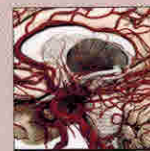110 Internal Carotid Artery



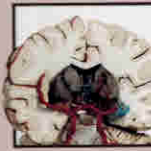111 Internal Carotid Artery



112 Anteromedial View



113 Medial View



114 Deep Arteries



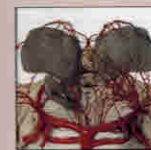115 Deep Arteries



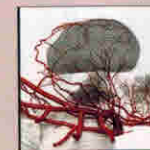
116 Deep Arteries



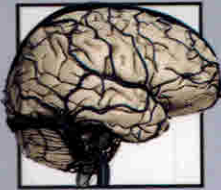117 Deep Arteries



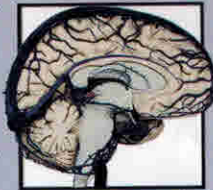
118 Deep Arteries



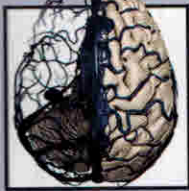119 Deep Arteries



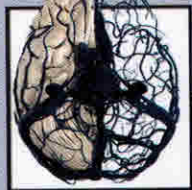
122 Superficial vein. Lateral View



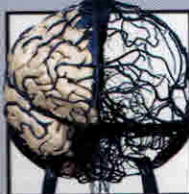
123 Superficial vein. Medial View



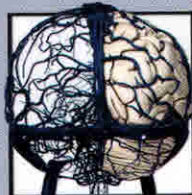
124 Superficial vein. Superior View



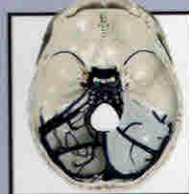
125 Superficial vein. Inferior View



126 Superficial vein. Anterior View



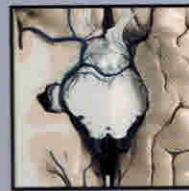
127 Superficial vein. Posterior View



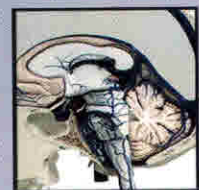128 Sinuses, Superior View



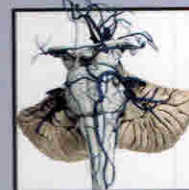
129 Sinuses. Medial View



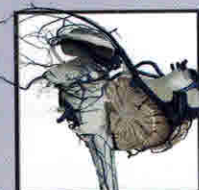
130 Deep Veins. Inferior View



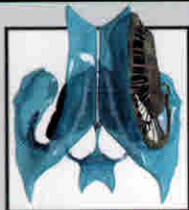131 Deep Veins. Medial View



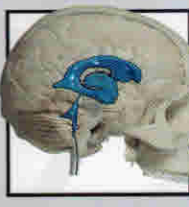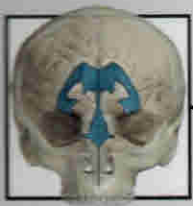
132 Veins of the Brainstem. Anterior View



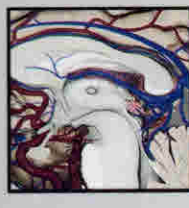
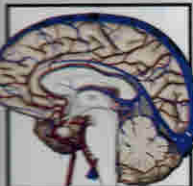
133 Veins of the Brainstem. Lateral View



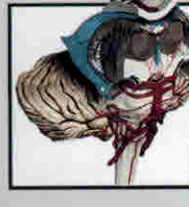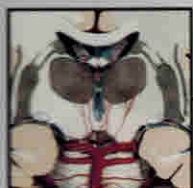136 Anterior View and Lateral View



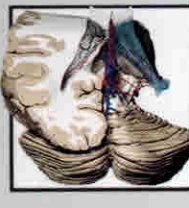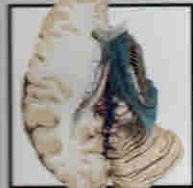137 Superior View and Posterior View



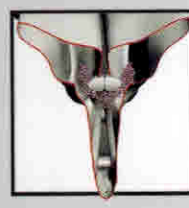138 Anterior View and Superior View




139 Lateral View and Posterior View




140 Middle Sagittal View



141 Middle Sagittal View



142 Section of the Ventricular System



143 Section of the Ventricular System

144 Superior View

145 Posterior View

146 Anterolateral View

147 Section of the Third Ventricle



150 Anterior View



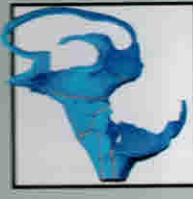151 Posterior View



152 Superior View



153 Inferior View



154 Lateral View



155 Anterolateral View



156 Sections of the Cisterns



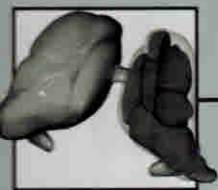
157 Sections of the Cisterns




158 Sections of the Cisterns



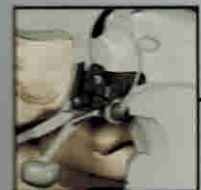
159 Sections of the Cisterns



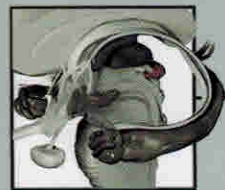
162 Thalamus



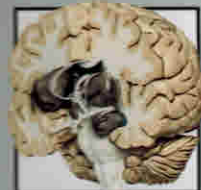163 Thalamus



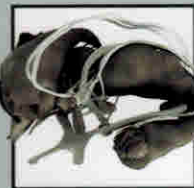164 Hypothalamus



165 Amygdaloid Complex



166 Basal Ganglia and Hippocampus



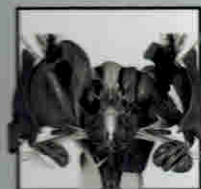
167 Basal Ganglia and Hippocampus



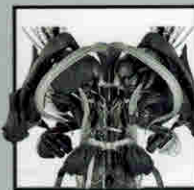
168 Connections of the Basal Ganglia



169 Connections of the Basal Ganglia



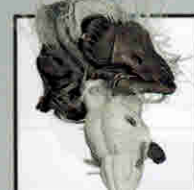170 Deep Gray Matter



171 Deep Gray Matter



172 Deep Gray Matter



173 Deep Gray Matter



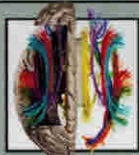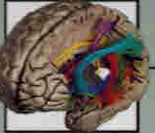174 Deep Gray Matter



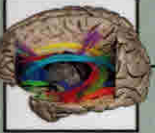175 Deep Gray Matter



178 All Fibres



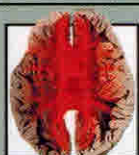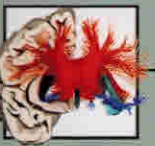179 All Fibres



180 Associative Fibres

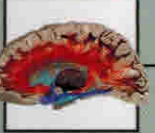181 Associative Fibres

182 Associative Fibres



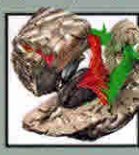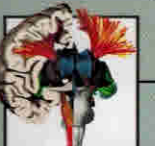183 Associative Fibres

184 Commissural Fibres



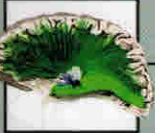185 Commissural Fibres

186 Commissural Fibres



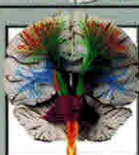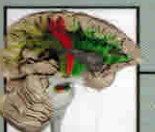187 Commissural Fibres

188 Projection Fibres



189 Projection Fibres

190 Projection Fibres



191 Projection Fibres

192 Projection Fibres



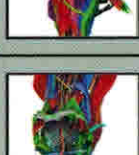193 Projection Fibres

194 Fibres of the Brainstem




195 Fibres of the Brainstem

196 Fibres of the Brainstem

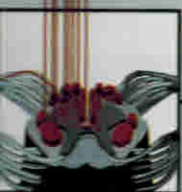
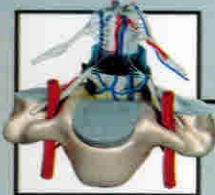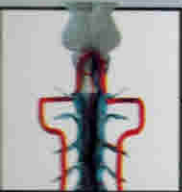

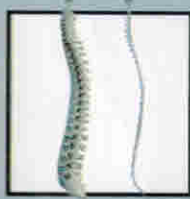
197 Fibres of the Brainstem

198 Fibres of the Brainstem



199 Fibres of the Brainstem



202 Anterior View

203 Lateral View

204 Spinal Arteries and Arachnoid

205 Spinal Veins and Dura Mater

206 Section of the Spinal Cord

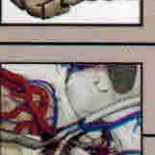
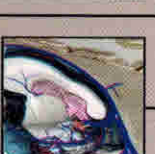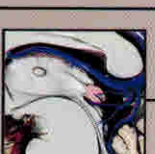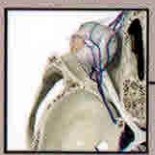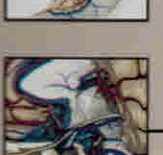
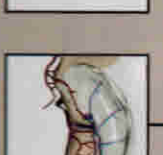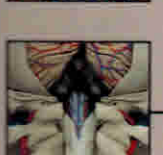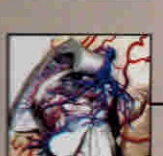
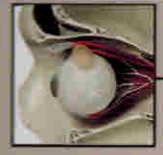207 Section of the Spinal Cord

208 Pyramidal system

209 Extrapyramidal system

210 Sensory System

211 Sensory System



214 Orbital Region

215 Orbital Region

216 Arteries of the Orbit

217 Veins of the Orbit

218 Cavernous Sinus

219 Cavernous Sinus

220 Pontocerebellar Angle

221 Pontocerebellar Angle

222 Pineal Region

223 Pineal Region

224 Pineal Region

225 Pineal Region

226 Fourth Ventricle

227 Fourth Ventricle

228 Hippocampal Formation

229 Hippocampal Formation

230 Hippocampal Formation

231 Hippocampal Formation

232 Chiasmal Region

233 Chiasmal Region